


PAIN MANAGEMENT

PROCEDURE / CPT CODE	MODALITY	COMMON INDICATIONS	PRE PROCEDURE CONSULTATION	PRE PROCEDURE IMAGING	PRE PROCEDURE LABS	POST PROCEDURE FOLLOW-UP	SEDATION AVAILABLE
INTERVENTIONAL PROCEDURES							
JOINT INJECTION Steroid medication is injected into the symptomatic joint to decrease pain and swelling. MULTIPLE	IR / US	Pain, DJD	PRN		See anticoagulation considerations. <i>(found in Preprocedure Considerations)</i>	Referring physician or UVIA Clinic or UVPM Clinic	No
SPINAL INJECTION (EPIDURAL, NERVE ROOT, FACET, AND SACROILIAC) Anesthetics and/or steroid medications are injected in the spine to reduce back and/or leg pain. These can be both diagnosed and therapeutic and include epidural, nerve root, facet, and sacroiliac joint injections. MULTIPLE	IR / US or CT	Axial and radicular pain	PRN	Yes	See anticoagulation considerations. <i>(found in Preprocedure Considerations)</i>	Referring physician or UVIA Clinic or UVPM Clinic	Yes
RADIO FREQUENCY A small catheter is inserted near the nerves arising from the back and heat is used to ablate the nerve sheath. MULTIPLE	IR	Pain, DJD	PRN	Yes	See anticoagulation considerations. <i>(found in Preprocedure Considerations)</i>	Referring physician or UVIA Clinic or UVPM Clinic	
VERTEBROPLASTY / KYPHOPLASTY Fluoroscopy is used to place a needle into a fractured vertebra. Bone cement is then injected to stabilize the fracture. MULTIPLE	IR	Acute compression fracture	Yes	Yes, may require a consult. Must have either MRI or CT + bone scan prior to evaluation.	See anticoagulation considerations. <i>(found in Preprocedure Considerations)</i>	Referring physician or UVIA Clinic or UVPM Clinic	Yes


PAIN MANAGEMENT

PROCEDURE / CPT CODE	MODALITY	COMMON INDICATIONS	PRE PROCEDURE CONSULTATION	PRE PROCEDURE IMAGING	PRE PROCEDURE LABS	POST PROCEDURE FOLLOW-UP	SEDATION AVAILABLE
INTERVENTIONAL PROCEDURES							
SACROPLASTY CT is used to guide needles into a fractured sacrum. A mixture of bone cement and contrast is then injected into the sacrum through the needles to stabilize the fracture.	CT or IR	Acute insufficiency fracture	Yes	Yes, may require a consult. Must have either MRI or CT + bone scan prior to evaluation.	See anticoagulation considerations. <i>(found in Preprocedure Considerations)</i>	Referring physician or UVIA Clinic or UVPM Clinic	Yes


PAIN MANAGEMENT

PROCEDURE / CPT CODE	MODALITY	COMMON INDICATIONS	PRE PROCEDURE CONSULTATION	PRE PROCEDURE IMAGING	PRE PROCEDURE LABS	POST PROCEDURE FOLLOW-UP	SEDATION AVAILABLE
INTERVENTIONAL PROCEDURES							
LUMBAR PUNCTURE / EPIDURAL INJECTION Fluroscopy is used to guide a small needle into or around the spinal canal. 62311	IR	Headache, meningitis, white matter disease,	PRN		See anticoagulation considerations. <i>(found in Preprocedure Considerations)</i>	Referring physician or UVIA Clinic or UVPM Clinic	Yes
EPIDURAL BLOOD PATCH Epidural Blood Patch (EBP) is used to treat spinal headaches that are most commonly encountered after dural puncture. The blood patch acts as a gelatinous glue which prevents cerebrospinal fluid (CSF) leakage and allows the dura hole to heal. 62273	IR	Spinal headache (CSF leak)	PRN		See anticoagulation considerations. <i>(found in Preprocedure Considerations)</i>	Referring physician or UVIA Clinic or UVPM Clinic	Yes

NECK / BACK PAIN

Algorithm for Interventional Pain Management for Pain of Spinal Origin

(Note--this does not include physical therapy, pharmacological management or psychological strategies including interdisciplinary pain management strategies that may be helpful in patients with chronically painful conditions)

I. Facet joint pain

- Diagnostic medial branch blocks
- Medial branch radiofrequency lesioning if medial branch blocks confirm facet joint pain

II. Discogenic pain

- Interlaminar epidural steroid injection.
- If unresponsive and pain is severe, consider consultation with a spine surgeon
- A diagnostic discogram may be considered pre or post surgical consultation

III. Muscular pain

- Trigger point injections may be helpful

I. Facet joint pain

- Diagnostic medial branch blocks
- Medial branch radiofrequency lesioning if medial branch blocks confirm facet joint pain
- Occasionally intra-articular injections are performed instead of radiofrequency lesioning

II. Discogenic pain

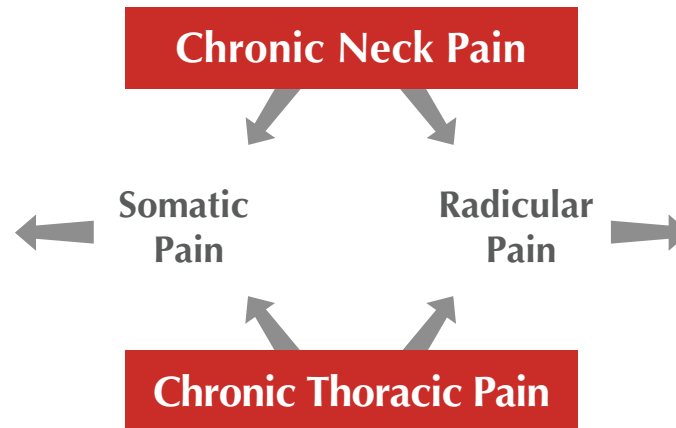
- Epidural steroid injection (interlaminar versus transforaminal depending on pathology)
- If unresponsive and pain is severe, consider consultation with a spine surgeon.
- A diagnostic discogram may be considered pre or post surgical consultation

III. Sacroiliac joint pain

- Sacroiliac joint intra-articular injection
- If response only temporary, consider combining sacroiliac joint injection with sacroiliac joint radiofrequency (literature not as supportive for this option).

IV. Muscular pain

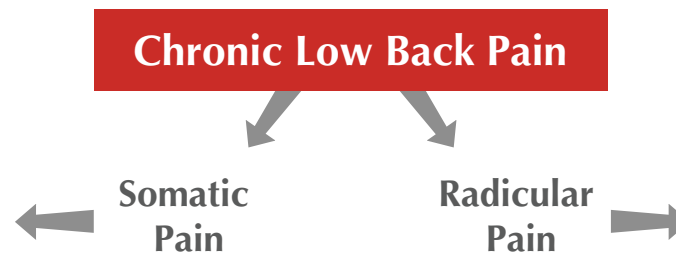
- Trigger point injections may be helpful



- If progressive neurological deficit, spine surgery consultation is necessary.

Otherwise

- Consider interlaminar epidural steroid injection.
- If unresponsive and pain is severe, consider spine surgeon consultation
- If prior history of spine surgery, and not a candidate for further surgery, consider spinal cord stimulation



- If progressive neurological deficit, spine surgery consultation is necessary.

Otherwise

- Consider interlaminar epidural steroid injection.
- If unresponsive and pain is severe, consider spine surgeon consultation
- If prior history of spine surgery, and not a candidate for further surgery, consider spinal cord stimulation